


available at www.sciencedirect.comjournal homepage: www.europeanurology.com/eufocus

Stone Disease

European Association of Urology Section of Urolithiasis and International Alliance of Urolithiasis Joint Consensus on Retrograde Intrarenal Surgery for the Management of Renal Stones

Guohua Zeng^{a,*}, Zhijian Zhao^{a,1}, Giorgio Mazzone^b, Margaret Pearle^c, Simon Choong^d, Andreas Skolarikos^e, John Denstedt^f, Christian Seitz^g, Daniel Olvera Pasada^h, Cristian Fioriⁱ, Andrea Bosio^j, Athanasios Papatsoris^k, Carlos Enrique Méndez Probst^l, Daniel Perez Fentes^m, Kah Ann Gitⁿ, Qinghui Wu^o, Oliver Wiseman^p, Esteban Emiliani^q, Yasser Farahat^r, Mehmet Ilker Gökçe^s, Stilianos Giannakopoulos^t, Ioannis Goumas Kartalas^u, Bhaskar Somani^v, Thomas Knoll^w, Jean de la Rosette^x, Jiehui Zhong^a, Marcus Vinicius Marocolo^y, Iliya Saltirov^z, Ben Chew^{aa}, Kunjie Wang^{bb}, Sven Lahme^{cc}, Guido Giusti^{dd}, Stefania Ferretti^{ee}, Sung Yong Cho^{ff}, Petrisor Geavlete^{gg}, Ramon Cansino^{hh}, Guido M. Kamphuisⁱⁱ, Daron Smith^d, Brian R. Matlaga^{jj}, Khurshid D. Ghani^{kk}, Norberto Bernardo^{ll}, Andres D. Silva^{mm}, Anthony C.F. Ngⁿⁿ, Sixing Yang^{oo}, Xiaofeng Gao^{pp}, Olivier Traxer^{qq}, Arkadiusz Miernik^{rr}, Evangelos Liatsikos^{ss}, Kandarp Priyakant Parikh^{tt}, Mordechai Duvdevani^{uu}, Antonio Celia^{vv}, Takahiro Yasui^{ww}, Albert Aquino^{xx}, Mohammad Alomar^{yy}, Vorapot Choonhaklai^{zz}, Bulent Erkurt^{ab}, Jonathan Glass^{ac}, Seshadri Sriprasad^{ad}, Palle J. Ooster^{ae}, Francis X. Keeley Jr.^{af}, Glenn M. Preminger^{ag}, Marcos Cepeda Delgado^{ah}, Edgar Beltran Suarez^{ai}, Zhangqun Ye^{aj}, Kemal Sarica^{ak,*}

^a Department of Urology and Guangdong Key Laboratory of Urology, The First Affiliated Hospital of Guangzhou Medical University, Guangzhou, China; ^b Department of Urology, San Bassiano Hospital, Vicenza, Italy; ^c Department of Urology, University of Texas Southwestern Medical Center, Dallas, TX, USA; ^d Institute of Urology, University College Hospital London, London, UK; ^e Second Department of Urology, Sismanoglio General Hospital, Athens, Greece; ^f Division of Urology, Western University, London, ON, Canada; ^g Department of Urology, Vienna General Hospital, Medical University of Vienna, Vienna, Austria; ^h Department of Urology, Hospital Zambrano Hellion, TecSalud, San Pedro Garza García, Mexico; ⁱ Department of Urology, San Luigi Gonzaga Hospital, University of Turin, Turin, Italy; ^j Department of Urology, Città della Salute e della Scienza, Molinette University Hospital, Turin, Italy; ^k Department of Urology, Sismanoglio General Hospital, Athens, Greece; ^l Department of Urology, Instituto Nacional de Ciencias Médicas y Nutrición Salvador Zubirán, Mexico City, Mexico; ^m Department of Urology, University Hospital Complex of Santiago de Compostela, Santiago de Compostela, Spain; ⁿ Department of Urology, Pantai Hospital, Penang, Malaysia; ^o Urology Center, National University Hospital, Singapore; ^p Department of Urology, Cambridge University Hospitals, Cambridge, UK; ^q Department of Urology, Fundació Puigvert, Barcelona, Spain; ^r Department of Urology, Sheikh Khalifa General Hospital, Umm Al Quwain, United Arab Emirates; ^s Department of Urology, Ankara University School of Medicine, Ankara, Turkey; ^t Department of Urology, Democritus University of Thrace, Alexandroupolis, Greece; ^u Department of Urology, Istituto Clinico Beato Matteo, Vigevano, Italy; ^v Department of Urology, University Hospital Southampton, Southampton, UK; ^w Department of Urology, Mannheim University Hospital, Mannheim, Germany; ^x Department of Urology, Medipol Mega University Hospital, Istanbul Medipol University, Istanbul, Turkey; ^y Hospital de Base of the Federal District, Brasília, Brazil; ^z Department of Urology and Nephrology, Military Medical Academy, Sofia, Bulgaria; ^{aa} Department of Urologic Sciences, University of British Columbia, Vancouver, BC, Canada; ^{bb} Department of Urology, West China Hospital of Sichuan University, Chengdu, China; ^{cc} Department of Urology, Siloah St. Trudert Hospital, Pforzheim, Germany; ^{dd} Department of Urology, IRCCS San Raffaele Hospital, Milan, Italy; ^{ee} Department of Urology, Hospital and University of Parma, Parma, Italy; ^{ff} Department of Urology, Seoul National University Hospital, Seoul National University College of Medicine, Seoul, Korea; ^{gg} Department of Urology, Saint John Emergency Clinical Hospital, Bucharest,

¹ These authors contributed equally to this work and are joint first authors.

* Corresponding authors. Department of Urology, Biruni University Medical School, Istanbul, Turkey (K. Sarica). Department of Urology and Guangdong Key Laboratory of Urology, The First Affiliated Hospital of Guangzhou Medical University, Guangzhou, China (G. Zeng).

E-mail addresses: gzyzgh@vip.tom.com (G. Zeng), saricakemal@gmail.com (K. Sarica), .

<https://doi.org/10.1016/j.euf.2021.10.011>

2405-4569/© 2021 European Association of Urology. Published by Elsevier B.V. All rights reserved.

Please cite this article as: G. Zeng, Z. Zhao, G. Mazzone et al., European Association of Urology Section of Urolithiasis and International Alliance of Urolithiasis Joint Consensus on Retrograde Intrarenal Surgery for the Management of Renal Stones, Eur Urol Focus (2021), <https://doi.org/10.1016/j.euf.2021.10.011>

Romania; ^{hh} Department of Urology, La Paz University Hospital, Madrid, Spain; ⁱⁱ Department of Urology, Amsterdam UMC, University of Amsterdam, Amsterdam, The Netherlands; ^{jj} Department of Urology, Johns Hopkins University School of Medicine, Baltimore, MD, USA; ^{kk} Department of Urology, University of Michigan, Ann Arbor, MI, USA; ^{ll} Department of Urology, Hospital de Clinicas Jose de San Martin, Buenos Aires, Argentina; ^{mmm} Department of Urology, Hospital del Salvador, Salvador, Chile; ⁿⁿ SH Ho Urology Centre, Department of Surgery, Prince of Wales Hospital, The Chinese University of Hong Kong, Hong Kong, China; ^{oo} Department of Urology, Renmin Hospital of Wuhan University, Wuhan, China; ^{pp} Department of Urology, Changhai Hospital, Second Military Medical University, Shanghai, China; ^{qq} Department of Urology, Tenon Hospital, Paris, France; ^{rr} Department of Urology, Faculty of Medicine, University of Freiburg Medical Centre, Freiburg, Germany; ^{ss} Department of Urology, University Hospital of Patras, University of Patras, Patras, Greece; ^{tt} Department of Genitourinary Surgery, Minimal Access Surgery Training Institute, Shyam Urosurgical Hospital, Ahmedabad, Gujarat, India; ^{uu} Department of Urology, Hadassah Hebrew University Hospital, Jerusalem, Israel; ^{vv} Department of Urology, San Bassiano Hospital, Bassano del Grappa, Italy; ^{www} Department of Nephrourology, Nagoya City University Graduate School of Medical Sciences, Nagoya, Japan; ^{xx} Department of Urology, Jose R. Reyes Memorial Medical Center, Manila, Philippines; ^{yy} Department of Urology, King Khalid University Hospital & Research Centre, Riyadh, Saudi Arabia; ^{zz} Departments of Urology and Surgery, Rajavithi Hospital, Bangkok, Thailand; ^{ab} Department of Urology, Istanbul Medipol University, Istanbul, Turkey; ^{ac} Department of Urology, Guy's and St. Thomas' NHS Foundation Trust, London, UK; ^{ad} Department of Urology, Darent Valley Hospital, Dartford and Gravesham NHS Trust, Dartford, UK; ^{ae} Department of Urology, Lillebaelt Hospital, Vejle, Denmark; ^{af} Bristol Urological Institute, North Bristol NHS Trust, Bristol, UK; ^{ag} Department of Urology, Duke University Medical Center, Durham, NC, USA; ^{ah} Department of Urology, Rio Hortega University, Valladolid, Spain; ^{ai} Department of Urology, Specialty Hospital La Raza, National Medical Center of the Mexican Institute of Social Security, Mexico City, Mexico; ^{aj} Department of Urology, Tongji Hospital, Tongji Medical College, Huazhong University of Science and Technology, Wuhan, China; ^{ak} Department of Urology, Biruni University, Medical School, Istanbul, Turkey

Article info

Article history:

Accepted October 20, 2021

Associate Editor: Christian Gratzke

Keywords:

Retrograde intrarenal surgery
Expert consensus
Delphi process

Abstract

Background: Retrograde intrarenal surgery (RIRS) has become the preferred treatment modality for nephrolithiasis. However, because of ongoing uncertainties regarding the optimal perioperative management, operative technique, and postoperative follow-up, as well as a lack of standardization for outcome reporting, consensus is needed to achieve more uniform clinical practice worldwide.

Objective: To develop recommendations for RIRS on the basis of existing data and expert consensus.

Design, setting, and participants: A protocol-driven, three-phase study was conducted by the European Association of Urology Section of Urolithiasis (EULIS) and the International Alliance of Urolithiasis (IAU). The process included: (1) a nonsystematic review of the literature to define domains for discussion; (2) a two-round modified Delphi survey involving experts in this field; and (3) an additional group meeting and third-round survey involving 64 senior representative members to formulate the final conclusions.

Outcome measurements and statistical analysis: The results from each previous round were returned to the participants for re-evaluation of their decisions during the next round. The agreement threshold was set at 70%.

Results and limitations: The panel included 209 participants who developed 29 consensus statements on the following topics of interest: (1) perioperative infection management; (2) perioperative antithrombotic therapy; (3) fundamentals of the operative technique; and (4) standardized outcome reporting. Although this consensus can be considered as a useful reference for more clinically oriented daily practice, we also acknowledge that a higher level of evidence from further clinical trials is needed.

Conclusions: The consensus statements aim to guide and standardize clinical practice and research on RIRS and to recommend standardized outcome reporting.

Patient summary: An international consensus on the best practice for minimally invasive surgery for kidney stones was organized and developed by two international societies. It is anticipated that this consensus will provide further guidance to urologists and may help to improve clinical outcomes for patients.

© 2021 European Association of Urology. Published by Elsevier B.V. All rights reserved.

1. Introduction

The prevalence of nephrolithiasis is increasing worldwide [1,2]. Retrograde intrarenal surgery (RIRS), shockwave lithotripsy (SWL), and percutaneous nephrolithotomy (PCNL) are the main modalities for the treatment of kidney stones. While PCNL is preferred for larger stones (>2 cm), RIRS is a good treatment option that competes with SWL for stones <2 cm [3]. Less invasive than PCNL but

with good stone-free rates (SFRs), RIRS has become increasingly popular as advances in technology and technique have improved its outcomes. However, several aspects of RIRS have been inadequately addressed in current clinical practice guidelines, and some technical details are not supported by large high-quality studies [4,5]. Thus, there has been a lack of clarity among endourologists as to which treatment recommendations should be followed.

In order to improve our understanding of the indications, application, follow-up, and outcomes for RIRS, globally applied consensus-based practice recommendations are urgently needed. Therefore, the European Association of Urology Section of Urolithiasis (EULIS) in collaboration with the International Alliance of Urolithiasis (IAU) conceived a project to develop consensus statements on RIRS.

2. Materials and methods

2.1. Literature review

The MEDLINE, Embase, and Scopus databases were searched for a non-systematic review of the literature from 2010 to the present. The keywords and Medical Subject Heading (MeSH) terms for the search strategy were as follows: “retrograde intrarenal surgery”, “RIRS”, “flexible ureteroscopy”, “fURS”, “ureterorenoscopy”, “URS”, “ureteroscopy”, “urolithiasis”, “kidney stones”, and “urinary tract stones”, either alone or in combination. Guidelines on urolithiasis from the European Association of Urology (EAU), the American Urological Association (AUA), and other associations were also included [3,6,7]. The findings from the non-systematic review provided the basis for the questions for voting in the Delphi survey and consensus meeting.

2.2. Implementation of the two-round modified Delphi survey

The project was carried out using a three-phase process based on the modified Delphi method, with the intent of promoting anonymity, controlling the influence of dominant or perceived authoritative voices, and providing controlled feedback to participants [8].

After completion of the literature review, a project steering committee was established that comprised an international and key member panel of 64 experts from EULIS and IAU, including two chairpersons (K.S. and G.Z.). This steering committee worked together to develop and modify a series of questions or statements relating to potential management strategies on the basis of their knowledge of the field. They recommended the names of known authoritative experts in the field according to a dedicated literature search or peer recommendations, with attention to geographic diversity to ensure representation of a well-distributed international experience. Finally, a total of 211 experts were invited, 209 of whom completed an anonymous online questionnaire via e-mail. Informed consent was obtained from the participants.

On the basis of prior studies and consensus method research, the “consensus agreement” level was fixed at 70% of participants [9]. For each question, the Delphi process was stopped either when agreement was reached or after completion of the second round. During the first round, participants were invited to suggest additional items for inclusion in the second round. When necessary, questions were iteratively revised. The results of the first-round survey were compiled and resent to the same participants, who were then asked to revisit their choices. Only the experts who had completed the first-round survey were invited to join the second round.

2.3. Consensus meeting and the third-round Delphi survey

After completion of the second round, an online consensus panel meeting was held with the participation of 16 members from the project steering committee to review the topics on which consensus was reached and to further discuss and reach consensus on those topics for which consensus was not reached after the second-round survey. These discussions were used to formulate and further refine these questions, which were then resent to the project steering committee with 64 key

members as the third round of the Delphi survey. Using the same consensus threshold, a final list of consensus statements was developed and ratified by participants.

3. Results

3.1. Two-round Delphi survey and consensus panel meeting

Among 211 experts invited to participate, 209 completed the first-round survey. After the second round, the response rate was 97.6% (204/209). Table 1 summarizes the characteristics of the 209 participants. Consensus was reached after round 2 for 25 out of 33 questions (75.8%). The remaining eight questions required further discussion. Following the third-round survey, consensus was also reached for four of these eight questions. Overall, agreement was achieved for 29 out of 33 statements (87.9%). The whole consensus survey is summarized in Figure 1.

3.2. Principal findings for the consensus topics

The detailed results for all statements are summarized in Table 2.

3.2.1. Preoperative evaluation and preparation

The panel did not recommend RIRS as the first option for stones >20 mm in size. The consensus panel proposed use of the largest diameter as a stone burden surrogate, although multiple alternatives are available. Noncontrast computed tomography (NCCT) was routinely recommended for preoperative imaging. Contrast-enhanced studies, such as intravenous urography and contrast-enhanced CT, were not recommended as routine investigations before RIRS.

For patients with a positive preoperative midstream urine (MSU) culture, 4–7 d of antibiotic treatment was deemed to be sufficient. The choice of antibiotic should be based on the culture-antibiogram findings. However, consensus was not reached regarding the necessity to repeat the culture before RIRS to assure sterile urine. For asymptomatic patients with a negative MSU but positive urine dipstick/urinalysis, the panelists could not reach consensus on the optimal management.

Another critical issue was the optimal timing of discontinuation of antiplatelet or anticoagulant agents. In this Delphi survey, agreement was reached that clopidogrel should

Table 1 – Characteristics of the 209 experts

Parameter	Result
Gender, n (%)	
Male	197 (94.2)
Female	12 (5.8)
Location of practice, n (%)	
Asia	61 (29.2)
Europe	122 (58.4)
North America	10 (4.8)
South America	12 (5.7)
Africa	4 (1.9)
Annual number of RIRS procedures, n (%)	
<30	54 (26)
30–50	34 (16)
50–100	59 (28)
100–150	29 (14)
150–200	12 (6)
>200	21 (10)
RIRS = retrograde intrarenal surgery.	

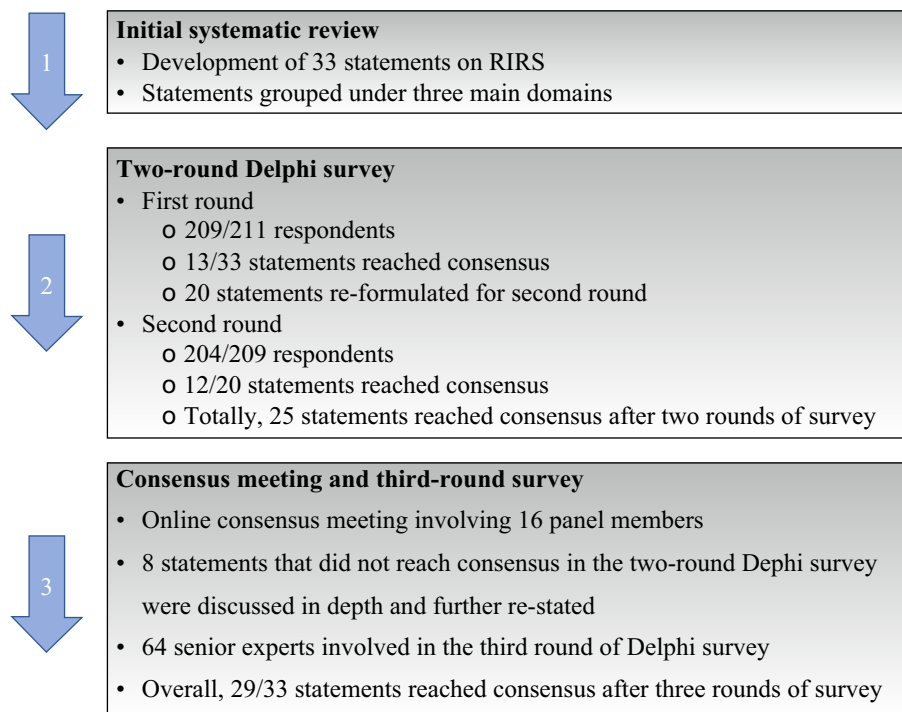


Fig. 1 – Overview of the development of the consensus statement. RIRS = retrograde intrarenal surgery.

be stopped at least 5–7 d before surgery. The need for bridging therapy should be based on the patient's thromboembolic risk. Consensus outcomes revealed that there was no need to stop aspirin before RIRS. It was recommended that warfarin should be discontinued 3–5 d before surgery, as well as dabigatran, rivaroxaban, and apixaban. However, no consensus was reached on the need for bridging therapy, and it was agreed that this should be decided according to an individual patient's circumstances.

3.2.2. Surgical procedure

Routine ureteral stenting was deemed unnecessary before RIRS. The panel concluded that pretreatment insertion of a ureteral stent is advisable only if a ureteroscope and/or ureteral access sheath (UAS) could not previously be placed through a narrow intramural ureter. In such cases requiring preliminary stenting, RIRS should ideally be carried out after 1–3 wk. In general, the experts agreed that use of a UAS was preferable, except in the case of small stones. Ideally, the tip of the UAS should be placed 1–2 cm below the ureteropelvic junction. Among panel members, 71% recommended initial semirigid ureteroscopy before UAS insertion in order to evaluate and/or dilate the ureter. In addition, utilization of a safety guidewire is generally advised.

Panelists were also queried regarding their preferences for laser lithotripsy techniques. A combination of dusting and fragmentation was considered optimal by most respondents. However, some experts preferred a single technique, either dusting, fragmentation, or the popcorn technique. The panel agreed that an appropriate dusting procedure involved the creation of fragments smaller than 2 mm.

A variety of irrigation systems are available, such as automatic pressured irrigation pumps, gravity-based bag

irrigation, and hand-operated irrigation. However, no consensus was reached regarding the optimal irrigation system.

The consensus panel recommended placement of internal ureteral stent at the conclusion of the procedure in most cases. In procedures with no ureteral injuries, removal of the stent within 1–2 wk was recommended.

When a staged RIRS is planned, the minimum interval between two sessions should be 4 wk to allow adequate time for effective fragment expulsion. The panel did not believe that α -blockers effectively increase the spontaneous passage of stone fragments. However, participants reached agreement that these agents could reduce stent-related symptoms and increase tolerability. The majority of the participants (87%) recommending using α -blockers for 3–4 wk after RIRS.

3.2.3. Standardization of outcome reporting

The panel agreed that a case should be considered "stone-free" in the absence of any residual stone or with the presence only of small residual fragments detected with NCCT. For residual fragments, a cutoff of 2 mm was recommended. The ideal time to evaluate stone clearance was thought to be 3 mo postoperatively. The operative time was defined as the duration from insertion of an endoscope into the urethra to its removal from the urethra. It was advised to avoid a total operative time exceeding 90 min.

4. Discussion

While RIRS continues to be favored as a promising and less invasive alternative in the management of moderate-sized kidney stones, clinicians should be aware of the ongoing uncertainty and controversies regarding several aspects of

Table 2 – Summary of statements and consensus status after three rounds of the Delphi survey

No.	Statement	Round 1		Round 2		Round 3		Final Status
		Agree	Status	Agree	Status	Agree	Status	
1	Stone burden is defined as the largest diameter	72%	Agree					Agree
2	If the maximum stone diameter is utilized, <20 mm stones are the best indication for RIRS	47%	Not reached	86%	Agree			Agree
3	A contrast-enhanced CT or IVP scan is not routinely required prior to RIRS	71%	Agree					Agree
4	A negative MSU culture is necessary after appropriate antibiotic treatment in cases with a positive initial MSU culture prior to RIRS	59%	Not reached	50%	Not reached	37%	Not reached	Not reached
5	In patients “with a positive MSU culture and antibiogram”, 4–7 d of antibiotic are recommended following antibiogram indications	55%	Not reached	72%	Agree			Agree
6	In asymptomatic patients with a recent negative MSU culture “but with positive urine dipstick/urinalysis findings”, antibiotic treatment is not recommended prior to RIRS	52%	Not reached	55%	Not reached	61%	Not reached	Not reached
7	Warfarin should be discontinued 3–5 d prior to RIRS; bridging therapy is necessary	55%	Not reached	71%	Agree			Agree
8	New anticoagulant agents (dabigatran, rivaroxaban, apixaban) should be discontinued 2–5 d prior to RIRS without any bridging therapy	43%	Not reached	61%	Not reached	48%	Not reached	Not reached
9	Discontinuation of aspirin prior to RIRS is not necessary	54%	Not reached	73%	Agree			Agree
10	Clopidogrel should be discontinued 5–7 d prior to treatment; eventual bridging therapy has to take in consideration the patient’s thromboembolic risk	77%	Agree					Agree
11	Ureteral stent placement is recommended if a ureteroscope and UAS fail to enter a narrow ureter	43%	Not reached	53%	Not reached	91%	Agree	Agree
12	Prior to RIRS, preliminary placement of a ureteral stent should not be routinely carried out	71%	Agree					Agree
13	In cases requiring a preliminary stent due to a narrow ureter, RIRS should be ideally carried out 1–3 wk afterwards	55%	Not reached	91%	Agree			Agree
14	A UAS should be routinely used during RIRS	72%	Agree					Agree
15	A 12–14 Fr UAS is mostly used during RIRS	90%	Agree					Agree
16	During RIRS, the best position for the UAS is 1–2 cm below the UPJ	70%	Agree					Agree
17	During RIRS, a UAS is not necessary in the case of treatment of small stones	34%	Not reached	58%	Not reached	81%	Agree	Agree
18	Semirigid ureteroscopy should be routinely performed at the beginning of RIRS to evaluate or dilate the ureter before accessing the kidney	71%	Agree					Agree
19	It is recommended to routinely use a safety guidewire during RIRS	74%	Agree					Agree
20	It is recommended to routinely use fluoroscopy to monitor UAS placement during RIRS	86%	Agree					Agree
21	The goal of an appropriate dusting procedure is to achieve fragments <2 mm after laser lithotripsy	40%	Not reached	94%	Agree			Agree
22	A combination of dusting and fragmentation is the preferred lithotripsy mode	60%	Not reached	88%	Agree			Agree
23	The operative time is defined as “from endoscope insertion into the urethra to its removal from the urethra”	55%	Not reached	86%	Agree			Agree
24	The maximum recommended operative time for single-stage RIRS should not exceed 90 min	45%	Not reached	55%	Not reached	86%	Agree	Agree
25	It is recommended to routinely place a ureteral stent after RIRS	85%	Agree					Agree
26	For procedures without any ureteral injuries, the stent is ideally removed within 1–2 wk	43%	Not reached	89%	Agree			Agree
27	The irrigation method to prioritize mainly depends on the availability of medical equipment in each center and the individual habits of surgeons	89%	Agree					Agree
28	The use of α -blockers is helpful in accelerating spontaneous passage of residual fragments following RIRS	32%	Not reached	44%	Not reached	38%	Not reached	Not reached
29	The use of α -blockers is recommended for a period of 3–4 wk after RIRS	57%	Not reached	87%	Agree			Agree
30	If a staged RIRS is necessary, to allow excretion of fragments, a minimum 4-wk interval between stages should be considered	44%	Not reached	74%	Agree			Agree
31	2 mm is defined as the “ideal” cutoff size for residual fragments after RIRS	56%	Not reached	71%	Agree			Agree
32	Low-dose NCCT is the recommended imaging modality to assess “residual fragments” after RIRS in adult patients	72%	Agree					Agree
33	The most suitable timing to assess stone clearance after RIRS is 3 mo postoperatively	32%	Not reached	53%	Not reached	73%	Agree	Agree

CT = computed tomography; IVP = intravenous pyelogram; MSU = midstream urine; NCCT = noncontrast CT; RIRS = retrograde intrarenal surgery; UAS = ureteral access sheath; UPJ = ureteropelvic junction.

the procedure. Very few clinical trials have focused on technological innovations and/or different techniques [5,10]. Consequently, there is a need for a consensus statement that can be used as a standard reference for urologists.

Although several reports have shown excellent success rates for the treatment of renal calculi of >2 cm with RIRS [11], the EAU guidelines recommend RIRS as an optimal treatment modality for stones \leq 2 cm and only recommend RIRS for stones >2 cm when PCNL is not possible [3]. In accordance with the outcomes of this survey, RIRS cannot be recommended as first-line treatment for stones >2 cm owing to the lower SFRs, higher risk of complications, and higher likelihood of requiring a staged procedure. Lower-pole calyceal stones are also challenging for RIRS, especially larger stones [12,13]. However, it is clear that PCNL is associated with more severe complications such as bleeding and infection [14].

Postoperative infection with fever and/or sepsis is a serious complication after RIRS [15]. Both the EAU and AUA guidelines recommend obtaining a urine culture and treating patients with a positive urine culture preoperatively [3,6]. In this consensus, 72% of panelists believed that a 4–7-d course of antibiotics constitutes sufficient therapy for a positive preoperative MSU culture. However, 63% of participants agreed that a subsequent negative MSU culture was not necessary before RIRS, and they conceded that it is not always possible to achieve a negative culture, particularly in patients with infected stones or indwelling stents. Despite recommendations, a simple urinalysis is commonly preferred as a clinical screening test because it is cheaper and fast to obtain. Pyuria and urinary nitrite levels are important markers of bacterial colonization; whether or not treatment is required is unclear but this is an important issue to consider [16]. After the third round of the survey, only 39.1% of the respondents believed that the presence of leukocytes and/or nitrites on preoperative urinalysis would require antibiotic treatment and therefore no consensus was achieved for this controversial topic. Further clinical trials should be conducted to better answer this question.

Clinicians must weigh the likelihood of perioperative bleeding against the thromboembolic risk [17]. Our panel did not recommend stopping aspirin, but clopidogrel should be stopped preoperatively. With respect to anticoagulant agents, two main categories were discussed, including warfarin and new anticoagulants. These should be stopped 2–5 d before the procedure; whether to offer bridging therapy depends on the individual thromboembolic risk. Studies investigating the safety of RIRS in patients on ongoing antithrombotic therapy are quite sparse [18,19]. Turna et al [18] evaluated 37 patients on warfarin, clopidogrel, or aspirin undergoing RIRS and observed no significant decrease in hemoglobin, emphasizing that RIRS is safe and effective in experienced hands. In another study conducted among 84 patients on continuous oral anticoagulation or antiplatelet therapy, the authors only stopped two procedures (2.3%) prematurely because of persistent bleeding; both patients were receiving warfarin [19].

The purpose of a ureteral safety guidewire is to provide access in the case of ureteral injury. However, there is little direct evidence to support routine use, and the presence of a safety guidewire can increase friction when passing the ureteroscope or UAS into the kidney [20–22]. It can also

increase the torque of the ureteroscope, making the procedure even more difficult [21,23]. Despite the lack of clear evidence to support its use, this consensus supports the use of a safety guidewire, especially when there is ureteral edema, stricture, abnormal anatomy, poor visualization, an encrusted ureteral stent, or impacted stones [20,23].

Some studies advocating routine preoperative stent placement cite better SFRs, fewer intraoperative complications, easier UAS placement, and effective drainage of an acutely obstructed infected kidney as reasons. However, this strategy also has some disadvantages, including additional anesthesia and hospital stays, a risk of encrustation and ureteral damage, additional radiation exposure, and higher costs [24,25]. Semirigid ureteroscopy is very useful for dilating a narrow ureter and can serve as an alternative to preoperative stenting, but special attention should be paid to prevent ureteral injuries and other complications [5,10,26].

The purpose of a UAS is to facilitate repeated access into the kidney and to maintain continuous outflow, thereby improving visibility and reducing intrarenal pressure. This may result in a shorter operative time and a lower risk of infection [27–30]. However, a UAS can also be a source of injury resulting in ureteral stenoses, obstruction, or hydronephrosis [27,30]. To date, the long-term risks of UAS placement have not been extensively investigated. However, the occurrence of ureteral strictures after RIRS is rare, reported for only 1.0% of patients [30]. UAS use may not be necessary in patients at low risk of infection and with a smaller stone burden [28]. Surgeon preference and clinical judgment are still fundamental factors in determining the need for UAS.

The EAU guidelines strongly recommend a holmium-YAG laser for lithotripsy [3,5]. New strategies for stone fragmentation and advances in laser technology provide for better and more versatile fragmentation/dusting capabilities while reducing retropulsion [31]. Several methods have been described, including dusting, fragmentation, popcorning, and combinations of these strategies, to achieve the desired outcome [32,33]. At present, there is only one prospective study comparing the efficacy of fragmentation versus dusting [34]. Complication rates, length of hospital stay, and the need for auxiliary procedures were similar. However, the operative time was significantly shorter for dusting, while the SFR favored fragmentation [34]. In our consensus, a combination of both strategies was preferred. The best strategy should be individualized on the basis of patient and stone characteristics.

The quality of visualization during RIRS is related to several factors, including the location and size of the UAS, the size of the flexible ureteroscope, the presence of endoluminal bleeding, and the irrigation characteristics and settings. Intrarenal pressure >40 mm Hg increases the risk of pyelovenous or pyelolymphatic backflow [35]. Consequently, it is essential to maintain an appropriate balance between inflow and outflow.

With the development of flexible ureteroscopes, routine use of indwelling ureteral stents has become controversial. According to the EAU guidelines, stent placement is not considered necessary after uncomplicated RIRS [3,36]. However, in this consensus we recommend internal ureteral stent placement at the conclusion of the procedure in most cases. We regret that the subgroup of patients with uncom-

plicated stones has not been investigated. The ideal stenting duration has not yet been identified, but most urologists in this study favored 1–2 wk [5,10,37].

Routine postoperative imaging is recommended to identify residual stones and confirm there is no obstruction. Our expert group defined the size for acceptable residual fragments as ≤ 2 mm. It is generally believed that residual stones ≤ 2 mm carry a minimal risk of causing postoperative stone-related complications during long-term follow-up [38].

The use of postoperative α -blockers could reduce stent-related symptoms and increase their tolerability, and some studies have even demonstrated that preoperative α -blockade may reduce maximal UAS insertion force and increase the SFR at follow-up [39,40], although we did not investigate this view in the consensus procedure.

Although there is ample published literature on RIRS, not all the studies are sufficiently rigorous because of heterogeneity in study patients and a lack of uniformity for treatment and follow-up. As a result, there is a dearth of high-quality trials to provide reliable clinical evidence to guide treatment. Our hope is that this consensus study will at least provide a framework for treating patients ureteroscopically in a generally uniform manner.

5. Conclusions

For this consensus we undertook a transparent approach to the ureteroscopic treatment of patients with stones with the objectives of decreasing the inconsistencies faced during routine clinical practice, reducing procedural complications and failures, and supporting standardized outcome reporting. Consensus was achieved for the majority of statements, including preoperative preparation, case selection, operative technique, and definition of reporting outcomes. Among the parameters evaluated in our consensus process, well-planned preoperative preparation, avoidance of ureteral injuries, careful control of the intrapelvic pressure, and judicious selection of cases were found to be the most important issues for safe and effective RIRS.

Author contributions: Kemal Sarica had full access to all the data in the study and takes responsibility for the integrity of the data and the accuracy of the data analysis.

Study concept and design: Zeng, Sarica.

Acquisition of data: Zeng, Zhao, Mazzon, Choong, Skolarikos, Denstedt, Seitz, Olvera Pasada, Fiori, Bosio, Papatsoris, Méndez Probst, Perez Fentes, Git, Wu, Wiseman, Emiliani, Farahat, Ilker Gökce, Giannakopoulos, Goumas Kartalas, Somani, Knoll, de la Rosette, Zhong, Marocco, Saltirov, Chew, Wang, Lahme, Giusti, Ferretti, Cho, Geavlete, Cansino, Kamphuis, Smith, Matlaga, Ghani, Pearle, Bernardo, Silva, Ng, Yang, Gao, Traxer, Miernik, Liatsikos, Parikh, Duvdevani, Celia, Yasui, Aquino, Alomar, Choonhaklai, Erkurt, Glass, Sriprasad, Osther, Keeley, Preminger, Cepeda Delgado, Beltran Suarez, Ye, Sarica.

Analysis and interpretation of data: Zeng, Zhao, Sarica.

Drafting of the manuscript: Zeng, Zhao, Mazzon, Sarica.

Critical revision of the manuscript for important intellectual content: Choong, Skolarikos, Denstedt, Seitz, Olvera Pasada, Fiori, Bosio, Papatsoris, Méndez Probst, Fentes, Git, Wu, Wiseman, Emiliani, Farahat, Ilker Gökce, Giannakopoulos, Goumas Kartalas, Somani, Knoll, de la Rosette.

Statistical analysis: Zeng, Zhao, Zhong.

Obtaining funding: None.

Administrative, technical, or material support: Zeng, Sarica.

Supervision: Sarica.

Other: None.

Financial disclosures: Kemal Sarica certifies that all conflicts of interest, including specific financial interests and relationships and affiliations relevant to the subject matter or materials discussed in the manuscript (eg, employment/affiliation, grants or funding, consultancies, honoraria, stock ownership or options, expert testimony, royalties, or patents filed, received, or pending), are the following: None.

Funding/Support and role of the sponsor: None.

References

- [1] Tundo G, Vollstedt A, Meeks W, Pais V. Beyond prevalence: annual cumulative incidence for kidney stones in the United States. *J Urol* 2021;205:1704–9. <https://doi.org/10.1097/JU.0000000000001629>.
- [2] Zeng G, Mai Z, Xia S, et al. Prevalence of kidney stones in China: an ultrasonography based cross-sectional study. *BJU Int* 2017;120:109–16. <https://doi.org/10.1111/bju.13828>.
- [3] Türk C, Neisius A, Petřík A, et al. *EAU guidelines on urolithiasis*. Arnhem, The Netherlands: European Association of Urology; 2020.
- [4] Ivan SJ, Sindhwani P. Comparison of guideline recommendations for antimicrobial prophylaxis in urologic procedures: variability, lack of consensus, and contradictions. *Int Urol Nephrol* 2018;50:1923–37. <https://doi.org/10.1007/s11255-018-1971-1>.
- [5] Falagarío UG, Calò B, Auciello M, Carrieri G, Cormio L. Advanced ureteroscopic techniques for the management of kidney stones. *Curr Opin Urol* 2021;31:58–65. <https://doi.org/10.1097/MOU.0000000000000835>.
- [6] Assimos D, Krambeck A, Miller NL, et al. Surgical management of stones: American Urological Association/Endourological Society guideline, part I. *J Urol* 2016;196:1153–60. <https://doi.org/10.1016/j.juro.2016.05.090>.
- [7] Taguchi K, Cho SY, Ng AC, et al. The Urological Association of Asia clinical guideline for urinary stone disease. *Int J Urol* 2019;26:688–709. <https://doi.org/10.1111/iju.13957>.
- [8] Williams PL, Webb C. The Delphi technique: a methodological discussion. *J Adv Nurs* 1994;19:180–6. <https://doi.org/10.1111/j.1365-2648.1994.tb01066.x>.
- [9] Witjes JA, Babjuk M, Bellmunt J, et al. EAU-ESMO consensus statements on the management of advanced and variant bladder cancer—an international collaborative multistakeholder effort under the auspices of the EAU-ESMO guidelines committees. *Eur Urol* 2020;77:223–50. <https://doi.org/10.1016/j.eururo.2019.09.035>.
- [10] Doizi S, Traxer O. Flexible ureteroscopy: technique, tips and tricks. *Urolithiasis* 2018;46:47–58. <https://doi.org/10.1007/s00240-017-1030-x>.
- [11] Jiang K, Zhang P, Xu B, et al. Percutaneous nephrolithotomy vs. retrograde intrarenal surgery for renal stones larger than 2cm in patients with a solitary kidney: a systematic review and a meta-analysis. *Urol J* 2020;17:442–8.
- [12] Resorlu B, Oguz U, Resorlu EB, Oztuna D, Unsal A. The impact of pelvicalyceal anatomy on the success of retrograde intrarenal surgery in patients with lower pole renal stones. *Urology* 2012;79:61–6. <https://doi.org/10.1016/j.urology.2011.06.031>.
- [13] Karim SS, Hanna L, Geraghty R, Somani BK. Role of pelvicalyceal anatomy in the outcomes of retrograde intrarenal surgery (RIRS) for lower pole stones: outcomes with a systematic review of literature. *Urolithiasis* 2020;48:263–70. <https://doi.org/10.1007/s00240-019-01150-0>.
- [14] Kallidonis P, Panagopoulos V, Kyriazis I, Liatsikos E. Complications of percutaneous nephrolithotomy: classification, management, and prevention. *Curr Opin Urol* 2016;26:88–94. <https://doi.org/10.1097/MOU.0000000000000232>.
- [15] Berardinelli F, De Francesco P, Marchioni M, et al. Infective complications after retrograde intrarenal surgery: a new standardized classification system. *Int Urol Nephrol* 2016;48:1757–62. <https://doi.org/10.1007/s11255-016-1373-1>.
- [16] Carlos EC, Youssef RF, Kaplan AG, et al. Antibiotic utilization before endourological surgery for urolithiasis: Endourological Society survey results. *J Endourol* 2018;32:978–85. <https://doi.org/10.1089/end.2018.0494>.
- [17] Dimitropoulos K, Omar MI, Chalkias A, Arnaoutoglou E, Douketis J, Gravas S. Perioperative antithrombotic (antiplatelet and anticoagulant) therapy in urological practice: a critical assessment

- and summary of the clinical practice guidelines. *World J Urol* 2020;38:2761–70. <https://doi.org/10.1007/s00345-020-03078-2>.
- [18] Turna B, Stein RJ, Smaldone MC, et al. Safety and efficacy of flexible ureterorenoscopy and holmium:YAG lithotripsy for intrarenal stones in anticoagulated cases. *J Urol* 2008;179:1415–9. <https://doi.org/10.1016/j.juro.2007.11.076>.
- [19] Altay B, Erkert B, Albayrak S. A review study to evaluate holmium: YAG laser lithotripsy with flexible ureteroscopy in patients on ongoing oral anticoagulant therapy. *Lasers Med Sci* 2017;32:1615–9. <https://doi.org/10.1007/s10103-017-2289-4>.
- [20] Dickstein RJ, Kreshover JE, Babayan RK, Wang DS. Is a safety wire necessary during routine flexible ureteroscopy? *J Endourol* 2010;24:1589–92. <https://doi.org/10.1089/end.2010.0145>.
- [21] Ulvik Ø, Wentzel-Larsen T, Ulvik NM. A safety guidewire influences the pushing and pulling forces needed to move the ureteroscope in the ureter: a clinical randomized, crossover study. *J Endourol* 2013;27:850–5. <https://doi.org/10.1089/end.2013.0027>.
- [22] Molina WR, Pessoa RR, da Silva RD, Gustafson D, Nogueira L, Meller A. Is a safety guidewire needed for retrograde ureteroscopy? *Rev Assoc Med Bras* 1992;2017(63):717–21. <https://doi.org/10.1590/1806-9282.63.08.717>.
- [23] Patel SR, McLaren ID, Nakada SY. The ureteroscope as a safety wire for ureteronephroscopy. *J Endourol* 2012;26:351–4. <https://doi.org/10.1089/end.2011.0406>.
- [24] Lee MH, Lee IJ, Kim TJ, Lee SC, Jeong CW, Hong SK, et al. The effect of short-term preoperative ureteral stenting on the outcomes of retrograde intrarenal surgery for renal stones. *World J Urol* 2019;37:1435–40. <https://doi.org/10.1007/s00345-018-2519-9>.
- [25] Yuk HD, Park J, Cho SY, Sung LH, Jeong CW. The effect of preoperative ureteral stenting in retrograde intrarenal surgery: a multicenter, propensity score-matched study. *BMC Urol* 2020;20:147. <https://doi.org/10.1186/s12894-020-00715-1>.
- [26] Boulalas I, De Dominicis M, Defidio L. Semirigid ureteroscopy prior retrograde intrarenal surgery (RIRS) helps to select the right ureteral access sheath. *Arch Ital Urol Androl* 2018;90:20–4. <https://doi.org/10.4081/aiua.2018.1.20>.
- [27] Lildal SK, Andreassen KH, Jung H, Pedersen MR, Osther PJS. Evaluation of ureteral lesions in ureteroscopy: impact of access sheath use. *Scand J Urol* 2018;52:157–61. <https://doi.org/10.1080/21681805.2018.1430705>.
- [28] Lima A, Reeves T, Geraghty R, Pietropaolo A, Whitehurst L, Somani BK. Impact of ureteral access sheath on renal stone treatment: prospective comparative non-randomised outcomes over a 7-year period. *World J Urol* 2020;38:1329–33. <https://doi.org/10.1007/s00345-019-02878-5>.
- [29] Shvero A, Herzberg H, Zilberman D, Mor Y, Winkler H, Kleinmann N. Is it safe to use a ureteral access sheath in an unstented ureter? *BMC Urol* 2019;19:80. <https://doi.org/10.1186/s12894-019-0509-x>.
- [30] Cooper JL, François N, Sourial MW, et al. The impact of ureteral access sheath use on the development of abnormal postoperative upper tract imaging after ureteroscopy. *J Urol* 2020;204:976–81. <https://doi.org/10.1097/JU.0000000000001147>.
- [31] Kronenberg P, Somani B. Advances in lasers for the treatment of stones—a systematic review. *Curr Urol Rep* 2018;19:45. <https://doi.org/10.1007/s11934-018-0807-y>.
- [32] Wenzel M, Bultitude M, Salem J. Dusting, fragmenting, popcorning or dustmenting? *Curr Opin Urol* 2019;29:108–12. <https://doi.org/10.1097/MOU.0000000000000580>.
- [33] Lildal SK, Andreassen KH, Baard J, et al. Consultation on kidney stones, Copenhagen 2019: aspects of intracorporeal lithotripsy in flexible ureteroscopy. *World J Urol* 2020;39:1673–82. <https://doi.org/10.1007/s00345-020-03481-9>.
- [34] Humphreys MR, Shah OD, Monga M, et al. Dusting versus basketing during ureteroscopy—which technique is more efficacious? A prospective multicenter trial from the EDGE research consortium. *J Urol* 2018;199:1272–6. <https://doi.org/10.1016/j.juro.2017.11.126>.
- [35] Osther PJS. Risks of flexible ureteroscopy: pathophysiology and prevention. *Urolithiasis* 2018;46:59–67. <https://doi.org/10.1007/s00240-017-1018-6>.
- [36] Quhal F, Seitz C. Guideline of the guidelines: urolithiasis. *Curr Opin Urol* 2021;31:125–9. <https://doi.org/10.1097/MOU.0000000000000855>.
- [37] Karagöz MA, Erihan IB, Doluoğlu ÖG, et al. Efficacy and safety of fURS in stones larger than 20 mm: is it still the threshold? *Cent Eur J Urol* 2020;73:49–54. <https://doi.org/10.5173/cej.2020.0056>.
- [38] Chew BH, Brotherhood HL, Sur RL, et al. Natural history, complications and re-intervention rates of asymptomatic residual stone fragments after ureteroscopy: a report from the EDGE research consortium. *J Urol* 2016;195:982–6. <https://doi.org/10.1016/j.juro.2015.11.009>.
- [39] Koo KC, Yoon J-H, Park N-C, et al. The impact of preoperative α -adrenergic antagonists on ureteral access sheath insertion force and the upper limit of force required to avoid ureteral mucosal injury: a randomized controlled study. *J Urol* 2018;199:1622–30. <https://doi.org/10.1016/j.juro.2017.09.173>.
- [40] Alsaikhan B, Koziaz A, Lee JY, Pace KT. Preoperative alpha-blockers for ureteroscopy for ureteral stones: a systematic review and meta-analysis of randomized controlled trials. *J Endourol* 2020;34:33–41. <https://doi.org/10.1089/end.2019.0520>.